

Electrohepatogram in pathologic liver conditions

Ahmed Shafik

Department of Surgery and Experimental Research, Faculty of Medicine, Cairo University, Cairo, Egypt

TABLE OF CONTENTS

1. Abstract
2. Introduction
3. Materials and Methods
 - 3.1. Subjects
4. Results
5. Discussion
6. Acknowledgement
7. References

1. ABSTRACT

We have recently studied the electric activity of the liver in both a normal canine model and in humans, and could characterize an electrohepatogram (EHG). Regular and reproducible slow waves or pacesetter potentials (PPs) were recorded. Hepatoarrhythmic electric activity was registered in liver insult of a canine model and in liver cirrhosis. The current communication studied the hepatic electric activity in liver diseases aiming at identifying an EHG for the different pathologic conditions, to be used as an investigative tool in their diagnosis. 55 subjects were studied: 10 with hepatocellular cancer (7 men, 3 women; age 53.7 years), 16 with acute hepatitis (10 men, 6 women; 42.2 years), 14 with metastatic liver deposits (9 men, 5 women; 53.1 years), and 15 healthy volunteers as controls (10 men, 5 women, 43.6 years). Three electrodes were placed 1.5 - 2 cm below and parallel to the costal margin and 4 to 5 cm apart. They were connected to a Beckman R611 recorder. At least two 20-minute recording sessions were performed for each subject. The PPs of the healthy volunteers exhibited a regular rhythm with identical and reproducible frequency and amplitude from the 3 electrodes in the same subject. The EHG of the hepatocellular cancer patients showed a 'hepatoarrhythmic' pattern; the waves had irregular frequency and amplitude. In acute hepatitis 2 patterns were encountered: 'silent', which occurred in the preicteric and icteric stages, and 'hepatoarrhythmic' which occurred in the convalescent stage. The liver which had a few metastatic deposits exhibited a hepatoarrhythmic pattern and the liver with numerous deposits presented a 'silent' pattern. The aforementioned patterns were reproducible. In conclusion, different patterns were recorded in the various liver diseases. The patterns seem to reflect the liver cell function. A normal EHG was recorded from the healthy liver, while a silent EHG was registered from the presumably non-functioning liver cells. Hepatoarrhythmia occurred probably when the liver function was impaired. Electrohepatography is a simple, easy, non-invasive, and non-radiologic procedure. It is suggested to serve as an investigative tool in the diagnosis of liver diseases.

2. INTRODUCTION

The liver may be involved in various pathologic conditions including bacterial or viral infections, cysts, tumors, cirrhosis, and others. These lesions can be diagnosed by sonography, CT scanning, magnetic resonance and/or liver biopsy (1,2).

Recently, we could record electric waves from the liver and characterize an 'electrohepatogram' (EHG) from the normal canine and human livers (3,4). The electric activity consisted of slow waves or pacesetter potentials (PPs). The waves were large, monophasic and positively deflected. They had a regular rhythm and were reproducible when the recording was repeated in the same animal or subject (3,4).

Liver insult in the canine model produced changes in the electric activity of the liver (3). Temporary clamping of the hepatic artery and portal vein produced a 'dysrhythmic EHG': the waves showed irregular rhythm, frequency and amplitude (3). In liver injury induced by irradiation we obtained 2 EHG patterns: dysrhythmic, and 'silent' in which no signals were recorded (3).

We studied also the electric activity in the cirrhotic liver (5). The PPs exhibited a dysrhythmic pattern which was consistent in all the recordings and reproducible in the individual subject.

In view of these results, we studied the hepatic electric activity in some of the liver diseases aiming at characterizing an EHG for these conditions that might serve as a diagnostic tool.

3. MATERIAL and METHODS

3.1. Subjects

The study comprised 55 subjects: 10 patients with hepatocellular cancer, 14 with metastatic deposits in the liver of patients with rectal cancer, 16 with acute

Electrohepatogram in liver pathologies

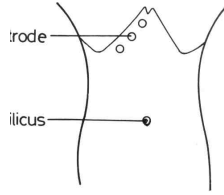


Figure 1. Sites of the electrodes for recording the hepatic electric activity (4).




Figure 2. Electrohepatogram of a healthy volunteer showing the pacesetter potentials with regular and identical frequency and amplitude from the 3 electrodes.

hepatitis (due to virus B in 6 and virus C in 10 patients), and 15 healthy volunteers who acted as controls. The clinical data of these subjects are shown in table 1. The study was approved by our Faculty Review Board and the Ethical Committee. The subjects gave an informed consent before entering the study.

The healthy volunteers had no history of liver disease. Their laboratory work was normal and abdominal sonography was unremarkable. All of the patients with hepatocellular cancer had liver cirrhosis following hepatitis B or C. The tumors were sited in the right lobe of the liver.

They had a mean transverse diameter of 7.3 ± 2.8 SD cm (range 6 – 8) and a vertical diameter of 8.4 ± 2.6 SD cm (range 7 – 9). Some of the tumors were located in the liver superficially and were palpable while others were situated deep in the liver tissue. The patients were selected among a population who had not yet received any form of treatment that might interfere with the electric activity. The hepatitis patients were examined for the electric activity a) during the acute pre-icteric stage in which the patients had fever, headache, anorexia, nausea and vomiting, b) during the icteric stage in which jaundice appeared, the fever dropped and nausea and vomiting diminished or disappeared, and c) in the convalescent stage in which the jaundice disappeared.

The patients with metastatic deposits in the liver had been operated upon for rectal cancer 14 – 23 (mean 20.6 ± 4.8 SD) months prior to the appearance of the deposits which were variable in size and number. The deposits were detected $\frac{1}{2}$ - 1 month prior to presentation. The patients were receiving irradiation for the recurrent rectal cancer, but up to the time of our recording the electric activity no systemic chemotherapy had been administered. The liver of the patients exhibited no pathology other than the metastatic deposits.

Technique of electrohepatographic recording:
The method of recording the hepatic electric activity was

described earlier (3-5) and will be mentioned briefly. After fasting for 12 hours, the subject was placed in the supine position, and uncovered from above the level of the 2 nipples to below the umbilicus. Three electrodes (SmithKline-Beckman, Los Angeles, CA, USA) were fixed by electrode gel to the abdominal skin. They were placed 1.5 - 2 cm below and parallel to the costal margin (Figure 1). The first electrode was placed 2.5 – 4 cm below and lateral to the xiphoid process, and the two remaining followed with a spacing of 4-5 cm. A reference electrode was applied to one of the lower limbs. The electrodes were connected to a Beckman R611 recorder (Sensor Medico, Anaheim, CA) with a time constant of 10 s, high frequency cutoff set at 0.08 Hz, and a paper speed of 1 mm/s. At least two 20-minute recording sessions were performed for each subject. Reproducibility of the electric signals was assessed during the periods of recording.

The results were analyzed statistically using the Student's t-test. Differences assumed significance at $p < 0.05$, and values were given as mean \pm standard deviation (SD).

4. RESULTS

The procedure was well accepted by the subjects. No adverse events were encountered during or after performing the examination, and all the individuals were evaluated.

Electrohepatogram in the healthy volunteers: PPs were recorded from the 3 electrodes of each subject. The waves had a regular rhythm, and were monophasic and positively deflected (Figure 2). The mean frequency was 8.8 ± 1.2 cycle/s (range 6-10) and amplitude 48.9 ± 11.7 μ V (range 40-66). These parameters had identical readings from the 3 electrodes of each subject and were reproducible when the recording was repeated in the same individual. The electric activity was present throughout all of the recording sessions.

Electrohepatogram in the hepatocellular cancer patients: The electric waves exhibited irregular rhythm, frequency and amplitude from the 3 electrodes of each subject. A hepatoarrhythmic pattern was recorded. The frequency and amplitude of the waves from each electrode had different readings in each session and also differed from one electrode to the other in the same patient (Figure 3). This picture occurred in both the superficially and deeply located tumors of the liver and was reproducible when the test was repeated in the individual subject.

Electrohepatogram in acute hepatitis patients: When the electric activity was recorded in the acute pre-icteric stage, no waves were registered during the whole recording sessions (Figure 4). This 'silent' pattern of EHG was recorded in all the patients.

Likewise, the silent pattern was recorded in the icteric stage; however, it was interrupted by a few scattered waves of low amplitude and irregular frequency (Figure 5). These scattered waves of electric activity were not always reproducible when the test was repeated in the same

Table 1. The clinical data of the 55 studied subjects

Diagnosis	No. of patients	Sex		Age (years)		Duration of disease (days)	
		M	F	Mean± SD	Range	Mean± SD	Range
Healthy volunteers	15	10	5	43.6±13.2	22-56	-	-
Hepatocellular cancer	10	7	3	53.7± 6.6	46-63	124.6±31.8	90-150
Acute hepatitis	16	10	6	42.2±10.8	32-53	4.2± 1.1	3-5
Metastatic deposits	14	9	5	53.1± 7.5	42-65	22.7± 6.5	15-30




Figure 3. Electrohepatogram of a patient with hepatocellular cancer showing 'hepatoarrhythmic' pattern. The pacesetter potentials have irregular frequency and amplitude which differ from one electrode to the other.



Figure 4. Electrohepatogram in the pre-icteric stage of acute hepatitis showing a 'silent' pattern; no electric waves were recorded.




Figure 5. Electrohepatogram in the icteric stage of acute hepatitis showing a 'silent' pattern interrupted by few irregular electric waves.




Figure 6. The hepatoarrhythmic pattern recorded in the convalescent stage of acute hepatitis.

subject. Sometimes, they were recorded from one electrode but not from the remaining two in the same patient.

When the electric activity was registered in the convalescent stage in which the jaundice had disappeared, a hepatoarrhythmic pattern was obtained (Figure 6). The waves had irregular rhythm, frequency and amplitude. They differed from one electrode to the other in the same

patient. This hepatoarrhythmic pattern was reproducible. Electrohepatogram in metastatic deposits in the liver: In the patients with 2 to 5 liver deposits, the liver exhibited hepatoarrhythmia. Frequency and amplitude had different readings not only in one and the same electrode during the recording sessions but differed also from one to the other electrode in the same patient.

The liver which had more than 5 metastatic deposits exhibited a 'silent' EHG and occasionally a few dysrhythmic waves. This pattern occurred in the 3 electrodes of the individual patient and was reproducible during the recording sessions.

5. DISCUSSION

The current communication demonstrated that liver diseases exhibited an electrohepatic pattern which was different from the one registered from the healthy volunteers. In hepatocellular cancer, the cause of the hepatoarrhythmic pattern might be that the tumor disturbs the electric activity emanated from the surrounding healthy cells or discharges waves of variable frequency and amplitude, probably due to the variability in cell activity of the tumor tissue. Alternatively, hepatoarrhythmia might be due to cirrhosis which affects the liver. All of the studied hepatocellular cancer occurred on top of a cirrhotic liver. Our recent studies have demonstrated a hepatoarrhythmic pattern in liver cirrhosis (5). The disturbed electric activity was related to the disappearance of the lobular architecture of the liver with formation of regeneration nodules which occur in liver cirrhosis. The hepatoarrhythmia was recorded from the superficially located and palpable tumors as well as from the deeply situated ones.

Two EHG patterns were identified in patients with acute hepatitis: silent and hepatoarrhythmic. The former occurred in the acute pre-icteric stage. The loss of electric activity is probably attributable to impairment of the cell function which seems to occur in the acute stage of the disease. At this stage, the liver cells are swollen and undergo degeneration and necrosis (6,7). The continuation of the silent pattern of EHG in the icteric stage seems to denote that the liver function is still impaired. However, the interruption of this silent activity with occasional few irregular waves might point to the start of the liver cell activity. In the convalescent stage, the electric activity of the liver appeared in an irregular and reproducible pattern which seems to be due to the irregular liver regeneration. The lobular architecture is lost and regeneration nodules appear haphazardly in the liver (6,7).

Electrohepatogram in liver pathologies

The 'silent' pattern of the EHG in the liver with numerous metastatic deposits is assumedly due to derangement of the liver cells. In addition to the metastatic deposits recorded by sonography, other microscopic deposits seem to be scattered all through the liver and disturb its function. The 'hepatoarrhythmia' recorded in the patients with few metastatic deposits is suggested to denote a disturbed function of the liver cells. It appears that in these cases the liver is not totally involved in the malignant process and that there are still functioning cells.

In conclusion, different EHG patterns were recorded in the various liver diseases. The discharge of the electric waves seems to depend on the integrity of the liver cells. A regular reproducible electric activity could be recorded from the normal liver. 'Silent' EHG appears to occur when the liver cells are not functioning, while hepatoarrhythmia occurs with impaired function of the cells. The electrohepatography is a simple, easy, non-invasive and non-radiologic procedure which is suggested to be used as an investigative tool in the diagnosis of liver diseases, provided a larger number of patients has been studied.

6. ACKNOWLEDGMENT

Margot Yehia and Waltraut Reichelt assisted in preparing the manuscript.

7. REFERENCES

1. Way L W. Liver. In: Current Surgical Diagnosis and Treatment. Way L W (ed), 10th edn. Norwalk, Connecticut: Appleton & Lange.505-519 (1994)
2. Soyer P, Levesque M, Elias D, Zeitoun G, Roche A: Preoperative assessment of resectability of hepatic metastases from colonic carcinoma: CT portography vs sonography and dynamic CT. *AJR* 159: 741-744 (1992)
3. Shafik A: Study of the electric activity of the liver with identification of a normal 'electrohepatogram' in a canine model. *Eur J Gastroenterol Hepatol* 11:1239-1243, (1999)
4. Shafik A: Transcutaneous electrohepatogram in humans. *Front Biosci*; 4: b1-4 (1999). PMID: 9989952.
5. Shafik A: Study of the electric activity of the cirrhotic liver with identification of a characteristic electrohepatogram. *Front Biosci* 4: b5-8. (1999) PMID:10331994
6. Poynard T, Bedossa P, Opolon P: Natural history of liver fibrosis progression in patients with chronic hepatitis C. *Lancet* 349: 825-832 (1997)
7. Lieber CS: Biochemical and molecular basis of alcohol-induced injury to liver and other tissues. *N Engl J Med* 319: 1639-1642 (1998)

Key words: Hepatocellular cancer, Metastatic deposits, Liver, Acute hepatitis, Slow waves, Pacemaker potentials

Send correspondence to: Ahmed Shafik, MD, PhD, 2 Talaat Harb Street, Cairo, Egypt, Tel/Fax: +20-2-349 8851, E-mail: shafisci@link.com.eg

This manuscript is available on line at:

<http://www.bioscience.org/2000/b/shafik/fulltext.htm>