

## Deep brain stimulation for refractory obsessive-compulsive disorder

Adam Burdick<sup>1</sup>, Wayne K. Goodman<sup>2</sup>, Kelly D. Foote<sup>1</sup>

<sup>1</sup>University of Florida, Department of Neurosurgery, PO Box 100265, Gainesville, FL, 32610, <sup>2</sup>University of Florida, Department of Psychiatry, 100 S. Newell Drive, Suite L4-100, Gainesville, FL 32611

### TABLE OF CONTENTS

1. Abstract
2. Introduction
3. Historical precedents
  - 3.1. Subcaudate tractotomy
  - 3.2. Cingulotomy
  - 3.3. Limbic leucotomy
  - 3.4. Anterior capsulotomy
  - 3.5. Comparisons and side effects
4. Pathophysiology
  - 4.1. Theory of parallel basal ganglia circuitry
  - 4.2. Neuroimaging evidence
5. Deep brain stimulation for OCD
  - 5.1. Background of DBS
  - 5.2. DBS for OCD
  - 5.3. Battery life
  - 5.4. Refining the target for OCD
  - 5.5. Programming
  - 5.6. Ethics
6. Perspective
7. Acknowledgments
8. REFERENCES

## 1. ABSTRACT

The use of deep brain stimulation (DBS) for obsessive compulsive disorder (OCD) is reviewed, including a brief discussion of historical groundwork in the surgical treatment of psychiatric disorders, and the rationale for the current practice. The theoretical neuroanatomic circuitry underlying the pathophysiology of OCD is presented, along with supporting neuroimaging and clinical evidence. The promising early results of DBS for OCD are summarized, including a discussion of current targets and programming issues. Finally, the ethical implications of the procedure are briefly discussed.

## 2. INTRODUCTION

Obsessive compulsive disorder (OCD) is characterized by disabling obsessions and compulsions. Obsessions are recurrent and persistent thoughts, impulses, or images that cause marked anxiety or distress. Compulsions are repetitive behaviors or mental acts performed in response to an obsession in order to prevent or reduce distress or some other dreaded event or situation. The compulsions are not realistically connected to the obsession, or are excessive (1).

With a worldwide prevalence of 3%, OCD is one of the most common psychiatric disorders, and in the US,

ranks among the top 10 diseases in terms of cost due to lost productivity (2). Affected patients often have difficulty carrying out everyday activities, maintaining social relationships, and working (3). The suicide risk of patients with anxiety disorders, which includes OCD, has been estimated to be 10 times the risk of the general population (4).

Conventional therapy for OCD has improved significantly over the past few decades. Current standard treatment combines selective serotonin reuptake inhibitors and atypical antipsychotics with cognitive-behavioral therapy (5-6). Although most patients improve with these interventions, data suggest that 20% to 40% are refractory (7-8). Current neurosurgical techniques and research are intended primarily for this group of patients with profound disability and poor quality of life despite the best available medical and behavioral therapy for their OCD.

### 3. HISTORICAL PRECEDENTS

The history of surgical intervention for psychiatric disorders is checkered (9). Following the award of the Nobel prize for medicine to Egas Moniz for the prefrontal leucotomy, psychosurgery fell into disfavor after widespread use of the prefrontal leucotomy and modifications of the procedure such as prefrontal lobotomy and transorbital leucotomy (“ice pick procedure”) produced a population afflicted with the complications of apathy, disinhibition and permanent personality changes (9-10). The heritage of this era is, of course, the controversy and suspicion widely held towards psychiatric surgery, but the lessons learned from this often tragic and marginally ethical psychosurgical experience also provided the foundation for later, more selective techniques that have been used for decades to treat psychiatric conditions such as depression and OCD (11). These techniques include subcaudate tractotomy, cingulotomy, limbic leucotomy, and capsulotomy. Overall, these newer procedures have repeatedly demonstrated efficacy for OCD, without the morbidity that haunted their predecessors (12-13).

Evaluation and comparison of these four surgical techniques is difficult because of the widely variable methodology used by their proponents. Standards of care, diagnostic criteria and outcomes measurements evolved over time, and investigators have been unable to find solutions to the practical and ethical restrictions that hinder blinded, randomized studies using sham surgeries on desperately ill psychiatric patients. Furthermore, due to the limited number of centers performing such operations, the evaluation of postoperative results has generally been performed by the same clinicians involved in the selection and operation of the patients, introducing a strong likelihood of bias (14). Finally, early researchers have frequently neglected to report the details of postoperative management, which could certainly have affected overall outcomes. Postoperative medical and psychiatric treatment could be enhanced by the surgical intervention (14-16). This last point certainly deserves more attention as current researchers methodically analyze the results of modern surgical series with uniform rating tools and more rigorously designed studies.

#### 3.1. Subcaudate tractotomy

Based on the observation—after 550 orbital undercutting operations—that the posterior part of the brain incision led to the best therapeutic effects, Knight introduced the more selective stereotactic *subcaudate tractotomy* in London in 1965 (17). The subcaudate tractotomy creates a lesion beneath the head of the caudate nucleus in the substantia innominata. Strom-Olsen reported 10 of 20 OCD patients achieving complete or near-complete recoveries after this procedure (18). Goktepe also reported 50% of 18 patients with ‘obsessional neurosis’ improved after subcaudate tractotomy (19). Bartlett extended the lesions in 8 patients who had at first responded, and then relapsed, after subcaudate tractotomy. He classified 50% of those relapsing patients as having again clinically responded after the second tractotomy (20). Though no longer used in the USA or Europe, subcaudate tractotomy has been recently performed in Seoul, Korea (21).

#### 3.2. Cingulotomy

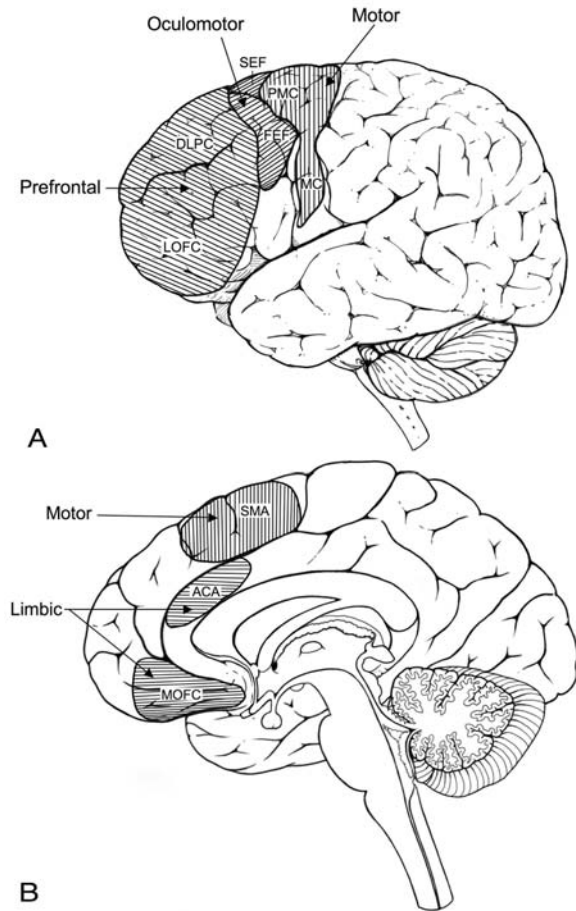
Radiofrequency ablation of the anterior cingulum has a low side effect and complication profile, and has been a leading neurosurgical treatment of OCD in North America for decades (9-10, 22). The procedure developed out of animal experimentation and lobotomy data that suggested interrupting connections between the cingulate gyri and orbitomedial frontal cortex was the source of its psychiatric therapeutic effects (11). In an early series of 32 patients, cingulotomy for OCD reportedly resulted in 25% of patients achieving functional wellness, 31% with marked improvement, and the remaining 44% having slight to no improvement (23). More recent studies commonly classify patients as “responders” if an intervention results in improvement of at least a 35% in the patient’s Yale-Brown Obsessive Compulsive Scale (Y-BOCS) score. Dougherty followed 44 patients after cingulotomy, of which 32% (14) were responders at 36 months, and 14% (6) were partial responders (24). In 2003, Kim reported 6 of 14 refractory OCD patients (43%) being responders at 12 months (25). Delayed benefit is not uncommon, and if by 6 months no response appears, a repeat procedure is frequently considered (10).

#### 3.3. Limbic leucotomy

Developed by Kelly and colleagues in the United Kingdom in 1973, *limbic leucotomy* combines both cingulotomy and subcaudate tractotomy (14,26). This procedure was designed to interrupt both the orbitofrontal-thalamic connections and the Papez circuit. Reports of improvement in the range of 80% exist, apparently better results than either component operation alone (13-14). However, those numbers were based on a subjective 5-point rating scale, and when patients were evaluated with clinically validated rating scales, treatment responders numbered only 35-50% (9).

#### 3.4. Anterior capsulotomy

Stereotactic *anterior capsulotomy* aims to interrupt fibers between the thalamus and the anterior frontal lobe, and was introduced by Talairach and then popularized by Leksell by the 1950s (10, 27-28). In his



**Figure 1.** A-B. The theory of parallel basal ganglia circuitry, while most well known for its motor loop, also pertains to nonmotor modalities and other cortical regions. Illustrated here is the lateral surface of a brain (A), showing the dorsolateral prefrontal cortex (DLPC), lateral orbitofrontal cortex (LOFC), frontal eye fields (FEF) and supplementary eye fields (SEF), premotor cortex (PMC) and motor cortex (MC); and the medial surface of a brain (B), showing the medial orbitofrontal cortex (MOFC), anterior cingulate area (ACA) and supplementary motor area (SMA). The limbic circuit includes the ACA and MOFC and has been associated with appropriate emotional and behavioral responses, and the prefrontal circuit includes the DLPC and LOFC and is associated with cognitive functions and appropriate behavioral set switches (e.g., perseveration when dysfunctional).

series of 35 OCD patients thus treated, Bingley noted that 16 (46%) were free of symptoms and 9 more (26%) were much improved. He further noted that smaller lesions in the ventral internal capsule were as efficacious as larger ones in the more dorsal capsule, suggesting an importance of the more ventrally located structures to its efficacy. Overall, cingulotomy results for OCD are comparable to those of the other procedures (11). Some concern has been raised, however, that the procedure may have a relatively high complication rate (9).

**3.5. Comparisons and side effects**

Keeping in mind the methodological variability that complicates any attempt to compare these operations, their overall effectiveness in OCD patients is about 67% (29). Chiocca’s review of 10 studies on these four surgical procedures comes to the conclusion that no one procedure is unequivocally best, but a few reports have favored capsulotomy over cingulotomy for OCD (9, 28, 30). The beneficial effects of these operations were commonly noted to take months to years to manifest (6, 24).

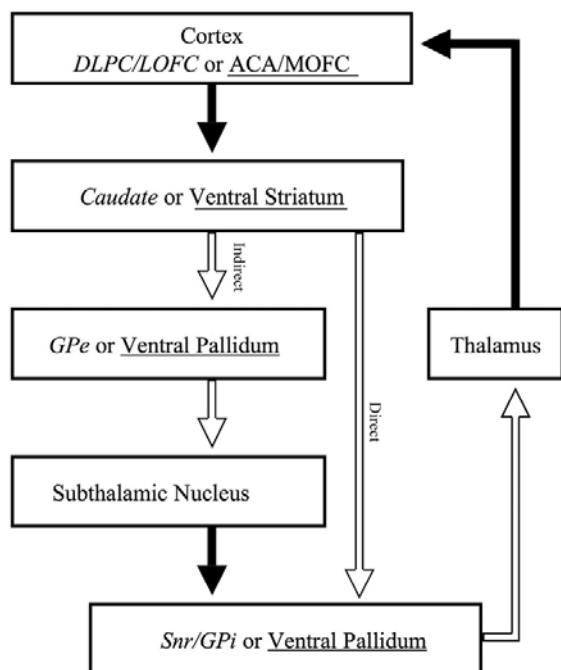
The side effect profile of these procedures has been relatively benign. Transient urinary incontinence, lethargy, weight gain and confusion have been reported (11,13). No evidence of reduced intellectual function was found in limited testing, but there has been evidence in some patients of increased perseverative behavior (11-12). Surgical complications are uncommon, with an estimated 0.3% incidence of hemiplegia after cingulotomy, and a risk of seizures of 1%-2.2% (19, 23). The striking apathy and personality changes common in the earlier history of psychosurgery have not been observed.

**4. PATHOPHYSIOLOGY**

The etiology, neuroanatomy, and neuropathophysiology that underlie OCD remain unknown, and no model has as yet explained the diverse phenomenology of behaviors, ratiocales, and intrusions these patients experience. Converging evidence from the fields of anatomy, genetics, radiology, neurochemistry, and neurosurgery is growing, however, and current hypotheses focus on dysfunctional circuitry between the frontal lobes and basal ganglia (31).

**4.1. Theory of parallel basal ganglia circuitry**

The *theory of parallel basal ganglia circuitry* forms the principle basis of the neuroanatomic and neurophysiologic understanding of OCD (32). Originally described by Alexander and colleagues in the late 1980’s, this theory is best known as a tool to understand the anatomy and circuitry of the basal ganglia in the context of movement disorders such as Parkinson’s disease (PD). In brief, it describes five cortico-striato-pallido-thalamo-cortical circuits, each subserving a different area of the cortex (Figure 1). Each circuit has both a reciprocal corticothalamic branch, and a corticostriatothalamic branch that modulates thalamic activity. In addition, the corticostriatothalamic branch has competing direct and indirect pathways (33). The direct pathway ultimately releases/excites the thalamus, and the indirect pathway brakes/inhibits the thalamus. In **Parkinson’s disease (PD)**, for example, loss of dopaminergic input to the basal ganglia results in dysfunction of the motor basal ganglia circuitry as follows: the *direct pathway is inhibited* by lack of excitatory dopamine input, resulting in loss of tonic thalamic excitation and a resultant paucity of movement. On the other hand, the *indirect pathway is overactive* due to a lack of inhibitory dopamine input, resulting in increased thalamic inhibition and further exacerbation of bradykinesia.



**Figure 2.** The prefrontal and limbic circuits connecting cortex to basal ganglia. Considered to be functionally distinct, they are combined together here to illustrate both simultaneously; italicized (*Prefrontal*) and underlined (Limbic) text distinguishes those elements that are not shared. Solid black arrows represent excitatory effects, and open arrows represent inhibitory effects. Theoretically, if there were insufficient inhibition of the corticothalamic segment, or simply primary corticothalamic overactivity, OCD symptoms could develop. How well developed the direct and indirect arms are in the limbic circuit is not clear.

Applying this theory to the understanding of **OCD** requires a focus on non-motor circuitry, including the limbic and prefrontal circuits. The *limbic circuit* begins in the anterior cingulate and medial orbitofrontal cortex, connects in series to the ventral striatum, the GPi/SNr, the mediodorsal nucleus of the thalamus, then back to the anterior cingulate cortex (34). In Alexander's original article, there is some uncertainty about how well developed the direct and indirect paths are in the limbic circuit. The *prefrontal circuit* begins in the *orbitofrontal cortex*, which regulates response inhibition, behavioral switches, and selection of appropriate cognitive and emotional responses, and the *dorsolateral prefrontal cortex*, which is involved in memory and executive functions (Figure 2) (12, 32). Dysfunction of the limbic circuit may be in the form of primary pathologic corticothalamic overactivity, or imbalance of the corticostriathalamic arm causing overall circuit overactivity (30). Supporting the use of this theoretical framework to understand the pathophysiology and treatment of OCD are the serendipitous results of two surgeons treating PD in patients with concomitant OCD. Mallet reported two patients with comorbid PD and OCD, who had relief of their psychiatric symptoms after subthalamic nucleus (STN) deep brain stimulation (DBS) was performed to ameliorate their motor symptoms (35).

Fontaine also implanted DBS leads bilaterally in the STN (involved in the indirect pathway) in a patient with both PD and OCD (36). The patient's OCD unexpectedly improved, which Fontaine speculated could be due to a restoration of the balance between dysfunctional pathways of a non-motor circuit. Mindus highlighted the anatomic importance of another target, the *internal capsule*, in the context of this theory of parallel basal ganglia circuitry, noting that aberrant positive feedback may be partially mediated by fiber bundles interconnecting thalamic nuclei and the orbitofrontal cortex (11). Modell also focuses on this circuit (the frontal-striatal-pallidal-thalamic-frontal loop), which passes through the anterior limb of the internal capsule, describing it as the only pathway for the reciprocal fiber bundles interconnecting the orbitofrontal cortex with the dorsomedial and related thalamic nuclei. He ascribes the selection of coherent, goal-oriented behaviors and emotions, and the elimination of unwanted responses, to the limbic system. All four operations (capsulotomy, tractotomy, limbic leucotomy, and cingulotomy) appear to disrupt connections between the orbitomedial areas of the frontal lobes and limbic or thalamic structures (9, 22).

#### 4.2. Neuroimaging evidence

Neuroimaging studies of OCD patients suggest abnormalities in these areas connected by the parallel basal ganglia circuitry: thalamus, basal ganglia, orbitofrontal cortex, and anterior cingulate cortex (37). These CT and MRI investigations suggest some patients might have abnormal basal ganglia development, describing a wide variety of findings in the volumes of the ventricles, caudate, white matter, cortex and striatum. Many of these findings are conflicting, however, such as reported findings of increased, decreased, and similar (to healthy controls) caudate volumes in OCD patients. This may reflect the fact that OCD isn't a single disorder, but an umbrella term for a variety of related conditions.

SPECT imaging has demonstrated perfusion abnormalities in the basal ganglia in OCD patients. Increased HMPAO (99m-technetium-*d,l*-hexamethyl propyleneamine oxime) uptake in medial frontal, dorsal parietal, orbitofrontal, and left posterofrontal cortex, suggests increased metabolic activity in these areas (37). FDG-PET (<sup>18</sup>F-fluorodeoxyglucose) studies have also implicated orbitofrontal cortex hypermetabolism in OCD patients compared to normal controls (37).

Bolstering these findings are the results of PET imaging of patients before and after effective treatment of OCD. Patients evaluated with PET scans after benefiting from chronic SSRI therapy have shown prominent decreases in metabolic activity in the orbitofrontal cortex (15). Likewise, a study evaluating OCD patients after DBS showed diminished metabolic activity in the orbitofrontal cortex in 2 (of 4 total) patients who had significant postoperative improvements in their Y-BOCS scores (15). Interestingly, one of the patients from that series who was a clinical non-responder to DBS showed no such decrease in orbitofrontal activity. In another study, six OCD patients treated with DBS underwent PET scanning during high frequency, low frequency, and off states (2). Significantly

**Table 1.** Published studies on DBS for OCD

Study	N	Results	Target	Comments
Jimenez (56)	1	Y-BOCS decreased from 36-40 to 15-20	Inferior thalamic peduncle	Effect maintained at 18 months
Greenberg (2)	10	4 of 8 responded (>35% decrease in Y-BOCS)	ALIC, anterior to rostral border of AC (ventral capsule/ ventral striatum)	Effects measured at 36 months One death from breast cancer, one patient at 24 months postop
Abelson (15)	4	2 of 4 responded (>35% decrease in Y-BOCS)	Base of the ALIC midpoint, at the junction with the NACC (shell of the NACC)	Effects measured over 4 random, blinded 3-week periods of on (two periods) and off (two periods)
Aouizerate (48)	1	Responder. 47% decrease in Y-BOCS	NACC, ventral caudate nucleus	Effects stable at 15 months
Fontaine (36)	1	Y-BOCS decreased from 32 to 1	STN	No OCD symptoms at 6 months DBS done for PD, not OCD
Nuttin (50)	6	4 of 6 responded (>35% improvement in Y-BOCS)	ALIC contacts 1, 2, 3; NACC contact #0 <sup>†</sup>	Effects maintained at least 21 months
Anderson (61)	1	76% decrease in Y-BOCS	18 mm lateral to midline, 13 mm anterior to the AC in the ALIC	Effect as measured at 3 months
Mallet (35)	2	81 and 83% decrease in Y-BOCS	STN, zona incerta, and in between	Effects as measured at 2 weeks DBS done for PD, not OCD

AC, anterior commissure; ALIC, anterior limb of the internal capsule; DBS, deep brain stimulation; N, number of patients; NACC, nucleus accumbens; OCD, Obsessive-compulsive disorder; PD, Parkinson’s Disease; STN, subthalamic nucleus; Y-BOCS, Yale-Brown Obsessive Compulsive Scale † Ventral contact is numbered zero (nearest the tip of the lead), and the successively more dorsal contacts are 1, 2 and 3 (most dorsal)

elevated regional cerebral blood flow was seen in the orbitofrontal cortex, anterior cingulate cortex, and putamen and globus pallidus during acute stimulation at the ventral anterior internal capsule/ventral striatum. These findings suggest that acute DBS in the ventral, anterior limb of the internal capsule is associated with activation of the circuitry implicated in OCD, and support the notion that DBS has remote as well as local effects in the brain. They also appear to contradict the previous, limited data showing downregulation of pathologically hyperactive orbitofrontal cortex after DBS for OCD, though it is conceivable that this represents an acute DBS effect only, and that chronic DBS at this target results in diminished orbitofrontal activity. Much further study is indicated to better understand the mechanism of action of OCD DBS, but this is an exciting field that is rapidly increasing our understanding of OCD and of limbic neurocircuitry in general.

**5. DEEP BRAIN STIMULATION FOR OCD**

**5.1. Background of DBS**

DBS has been successfully used since the early 1990s to treat movement disorders such as Parkinson’s disease, essential tremor and dystonia. DBS therapy involves chronic electrical stimulation of a specified target in the brain that results in beneficial modulation of a pathologically functioning neural circuit. In the case of essential tremor, for example, pathological electrical oscillations in the cerebello-thalamo-cortical pathway result in disabling postural and action tremor. It was previously discovered that creation of a lesion in the Vim thalamic nucleus (thalamotomy) interrupted the pathologically oscillating circuit and effectively suppressed the patient’s tremor. The modern era of DBS therapy was ushered in when Benabid *et al* employed chronic high frequency stimulation of the Vim thalamic nucleus to interrupt these pathological oscillations and suppress the tremor without intentional destruction of brain tissue in 1987 (38).

The precise *mechanism of action of DBS* is a matter of active research, but theories include interruption of pathologic neuronal activity, disruption of pathologic resonance patterns, activation of inhibitory afferent tracts, and/or activation of efferent tracts (15, 39, 40-42). The prevailing view currently is that high frequency stimulation reduces neural transmission by inactivating voltage dependent ion channels (9). In discussions of potential mechanisms of action of DBS for OCD, stimulation of the ventral anterior limb of internal capsule/ventral striatum has been postulated to modulate cortical and thalamic activity via orthodromic and antidromic effects (2). Downstream targets might be activated, inhibited, or both. Van Kuyck proposed that stimulation of the nucleus accumbens might act to release neurotransmitters from incoming afferents, and reported that orthodromic as well as antidromic neuronal activation was observed (43).

Notwithstanding the incomplete understanding of its mechanism of action, DBS has largely supplanted older ablative procedures, such as pallidotomy and thalamotomy, for the treatment of movement disorders in most modern centers due to its efficacy, reversibility, and flexibility. In theory, any pathologically functioning circuit in the brain could potentially be modulated with DBS. It follows that any disorder resulting from an identifiable pathological neural circuit could potentially be treated with DBS to therapeutic benefit. Researchers are currently investigating the potential therapeutic effects of DBS for various disorders including post-traumatic and multiple sclerosis related tremors, refractory gait disorders, epilepsy, OCD, depression, Tourette syndrome, eating disorders, minimally conscious state and cluster headaches (44-45).

**5.2. DBS for OCD**

To date, reports of over two dozen OCD patients who have received DBS have been published, with several more as yet unpublished (Table 1). In 1999, Nuttin *et al* reported the first successful DBS therapy for refractory OCD in three of four patients using DBS of the anterior

limb of the internal capsule (ALIC) bilaterally (46). This approach was analogous to Benabid's thalamic DBS approach, in that lesioning the ALIC (anterior capsulotomy) had previously shown therapeutic benefit for OCD. In anterior capsulotomy trials, several OCD patients who failed to respond to a single, more dorsal lesion in the ALIC responded when a second, more ventral ALIC lesion was added. Presumably, in order to recapitulate this positive high volume ALIC ablation experience, larger spinal cord stimulator leads were employed for OCD DBS in favor of the much smaller standard DBS leads. The Pisces Quad Compact Electrode, Model 3887, with 4 mm spacing and 3 mm contacts (Medtronic, Inc., Minneapolis, MN) was stereotactically implanted with the tip in or near the nucleus accumbens and the electrode array spanning the white matter of the anterior limb of the internal capsule. The large size of the active area of the lead contributes to an uncertainty of whether the beneficial target is one or a number of structures, however. The proposed explanation for the efficacy of this approach was that DBS resulted in therapeutic modulation of the malfunctioning fronto-striatal-pallidal-thalamic-frontal circuit that has been implicated in the pathology of OCD (31). Nuttin further tested the response over a longer period in a later series with 6 patients (47). Four of the patients were "responders" with decreases in the Y-BOCS score of at least 35%.

In an attempt to treat comorbid OCD and major depression in one treatment-refractory patient, Aouizerate *et al* targeted both the nucleus accumbens and the ventromedial caudate nucleus, implanting DBS leads bilaterally with contacts situated in both structures (48). Initial stimulation was restricted to the deeper contacts within the nucleus accumbens and, although depressive symptoms began to abate, OCD symptoms were unchanged at one month. At that point, contacts in the ventral caudate nucleus were also activated. At 15 months follow-up the patient's Y-BOCS score had dropped from 30 to <16 (47% decrease). Whether the effect was due to stimulation of the ventral caudate nucleus or delayed effects from the nucleus accumbens cannot be ascertained. Given the differential effects of DBS over time in their patient, the authors speculate that there are distinct neuronal networks subserving depression and OCD, or that functional reorganization of the networks occurs more slowly with OCD than with depression. Interestingly, in one patient the recurrence of clinical impairment revealed that the pulse generator battery had failed, with a rise in the patient's Y-BOCS score (49). Three months after generator replacement he again achieved remission levels in his Y-BOCS score.

Abelson's series of 4 OCD DBS patients targeted the base of the internal capsule, at its junction with the nucleus accumbens, with two out of four patients responding (15). Greenberg and colleagues published 3-year DBS follow-up data for a group of 10 patients with severe, refractory OCD implanted at the ventral capsule/ventral striatum, with four patients responding (one patient died of breast cancer, and another hadn't reached 3 years of follow-up) (16).

At the time of this writing, officials at Medtronic, Inc. (the supplier of the DBS devices) confirm that over 60 DBS procedures are known to have been performed worldwide for the treatment of severe, refractory OCD under investigational protocols. Results to date are promising, with two thirds of these severely disabled patients responding to DBS with a >35% decrease in YBOCS score. Based on these results, a Humanitarian Device Exemption has been applied for from the US Food and Drug Administration.

### 5.3. Battery life

Short battery life has been an unforeseen problem associated with DBS for OCD. The level of current required to achieve the reported beneficial effects has, in general, been substantially higher than that commonly required for the treatment of movement disorders. Nuttin attempted to prolong battery life, which ranged from 5 to 12 months in his series, by several strategies: low-consumption settings; turning the battery off at night; or by cycling the stimulator on one minute and off the next minute. None of these strategies was acceptable to the patients, who requested continuous, higher voltage and higher pulse width stimulation (50). Furthermore, unilateral stimulation was not as effective as bilateral stimulation. Tass has suggested novel on-demand settings for DBS in OCD patients as a means of extending battery life (51). In this method, judiciously applied electrical pulses are meant to desynchronize pathologic synchronicity, thus achieving clinical benefit with less current. Another potential solution for excessive energy consumption would be to identify a more efficacious target that might require lower current input to produce similar benefit. Some believe that the high DBS settings commonly required suggest that the optimal structure to be stimulated is at some distance from the current target.

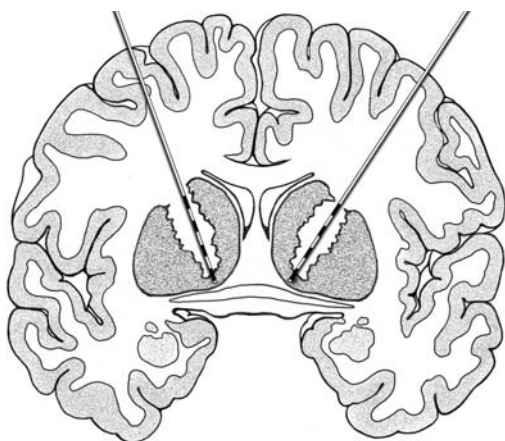
### 5.4. Refining the target for OCD

Refining the target for DBS in OCD is an area of intense interest. Ablative procedures have targeted the cingulum, the anterior limb of the internal capsule, and the substantia innominata, all disrupting connections between the striatum/basal ganglia and the frontal lobe. As discussed above, none of these targets has been proven unequivocally superior to the others. The ventromedial (VM) striatum has been proposed as a target, based on its role in the orbitofrontal cortex circuit and functional imaging studies (48, 52). Greenberg's assessment of the target used in his series, VC/VS (ventral capsule/ventral striatum), is that it is more posterior than traditional capsulotomy lesions and posterior to Abelson's and Aouizerate's targets, but lies in the same anterior-posterior plane as the nucleus accumbens. The nucleus accumbens has been identified as a potential target for OCD DBS based on clinical observations and anatomical/physiopathologic considerations (45, 48, 51, 53-54). Electrical stimulation of the nucleus accumbens has been associated with rewarding properties, activity, fight-or-flight behaviors and food intake, albeit with variable effects (43). Anatomically, it is situated at a nodal point, at the crossing of limbic projections from the amygdala, hippocampus, prefrontal and cingulate cortex (43, 55). In

**Table 2.** Stimulation parameters for OCD

Study	Amplitude	Frequency	Pulse width	Lead	Laterality
Jimenez (56)	5 V	130 Hz	450 msec	Model 3387	Bilateral
Greenberg (2)	8-17 mA	100-130 Hz	90-210 msec	Model 3387 IES <sup>1</sup>	Bilateral
Abelson (15)	5, 7, 7, 10.5 V	150 Hz, 1 <sup>st</sup> patient 130 Hz, 3 patients	60 msec, 1 <sup>st</sup> patient, 210 msec, 3 patients	Model 3387 <sup>2</sup>	Bilateral
Aouizerate (48)	4 V	130 Hz	120 msec	Model 3387	Bilateral
Fontaine (36)	3.5 V (Right) 1.3 V (Left)	185 Hz	60 msec	Model 3389 <sup>3</sup>	Bilateral
Nuttin (50)	4, 5.5, 7, 9, 10.5 V	100 Hz	200, 210, 450 msec	Model 3487A <sup>4</sup> (1 patient) Model 38875 (5 patients)	Bilateral
Anderson (61)	2V	100 Hz	210 msec	Model 3387	Bilateral
Mallet (35)	3.1, 3.2 V	130, 185 Hz	60, 90 msec	Model 3389	Bilateral

<sup>1</sup> Model 3387 IES: 3 mm contact length, 4 mm spacing (Medtronic, Inc., Minneapolis, MN), <sup>2</sup> Model 3387: 1.5 mm contact length, 1.5 mm spacing (Medtronic, Inc., Minneapolis, MN), <sup>3</sup> Model 3389: 1.5 mm contact length, 0.5 mm spacing (Medtronic, Inc., Minneapolis, MN), <sup>4</sup> Model 3487 A: 3 mm contact length, 6 mm spacing (Medtronic, Inc., Minneapolis, MN), <sup>5</sup> Model 3887: 3 mm contact length, 4 mm spacing (Medtronic, Inc., Minneapolis, MN)



**Figure 3.** This illustration shows an electrode with larger lead contacts and spacing, placed in the internal capsule with the ventral contact in the region of the nucleus accumbens, the most common target for OCD DBS. Attention to targeting has focused on the nucleus accumbens, ventral capsule, ventral striatum and inferior thalamic peduncle, with serendipitous results obtained in subthalamic nucleus/zona incerta stimulation for PD.

reports of anterior capsulotomy series, several groups have noted that the ventrocaudal portion of the lesions were crucial for therapeutic success, suggesting that accumbens-mediated modulation of amygdaloid-basal ganglia-frontal circuitry, rather than internal capsule fiber tracts, could be the actual target (54). Another proposed target is the magnocellular part of the dorsomedial nucleus of the thalamus, which has also previously been a target for lesioning in OCD (47). Even the STN has been proposed as a target based on the observation that PD patients with concomitant OCD had improvements in their Y-BOCS scores after STN DBS (35, 36). Recently, DBS of the inferior thalamic peduncle, which connects the thalamus to the orbitofrontal cortex, has been performed in a patient with OCD with good results (56). The majority of DBS leads implanted to date for the treatment of medically refractory OCD have targeted the ventral aspect of the anterior limb of the internal capsule and/or the nucleus

accumbens—the so-called ventral caudate/ventral striatum (VC/VS) target (Figure 3).

### 5.5. Programming

To explore the variable effects of stimulation on the circuitry in the VC/VS region, Okun and colleagues tested active vs. sham/placebo DBS programming in five OCD patients bilaterally implanted with leads deep and through the anterior commissure, into the approximate center of the nucleus accumbens (57). Stimulation induced side effects included non-mood related experiences like smell (metallic, odd, sweet, strange, roses/oil/almonds), taste (metallic, sour, odd), and physiologic responses (autonomic responses), as well as fear, panic and transient euphoria with an associated asymmetric smile. These effects were significantly associated ( $p=0.001$ ) with stimulation at the ventral lead contacts, and with higher voltages ( $p=0.001$ ). Higher voltages and contact location were significantly associated with mood and anxiety responses ( $p=0.001$ ), with ventral contacts significantly associated with worsened mood ( $p=0.001$ ) and unacceptable side effects ( $p=0.01$ ). Greenberg also noted anxiety and adverse effects with the ventral contacts (zero and one). In Okun's series, contact number one carried the greatest mood improvement. Pulse width was also significantly associated with physiologic and sensory responses, with 210 msec eliciting the greatest number and range of responses. However, no pulse width was significantly associated with mood or anxiety responses, or with unacceptable side effects. Neuron cell bodies and dendrites, small axons and large myelinated axons have been shown to respond best to different ranges of pulse widths (43). Okun theorizes that nucleus accumbens stimulation could activate one of the non-motor basal ganglia loops described by Alexander. Alternatively, stimulation of the nucleus accumbens or ventral capsular fibers might elicit limbic responses via circuit interconnectivity, as in Haber's proposed limbic-cognitive-motor interface mediated by the ventral midbrain (58). Van Kuyck noted that the nucleus accumbens is heterogeneous, with varying connections to other parts of the brain, and therefore the position of the electrode within the nucleus could alter the clinical results. A summary of the various published programming parameters is presented in (Table 2).

**Table 3.** Requirements for studies on DBS in psychiatric patients. From Nuttin,(60).

Proposed requirements for studies investigating Dbs use in psychiatric patients
1. An ethics committee that will have ongoing oversight of the project should approve the investigational protocol.
2. A patient assessment committee should evaluate each patient as a possible candidate for inclusion in the protocol. The role of this committee is to ensure that potential candidates meet certain medical and psychiatric criteria and are appropriate for inclusion in the study and to monitor the adequacy consent process. Patient assessment committees should be constituted broadly to achieve an ethically valid consensus, and they should have the opportunity to obtain independent capacity assessments when indicated.
3. Candidates for DBS surgery should meet defined criteria for severity, chronicity, disability, and treatment refractoriness.
4. The use of DBS should be limited solely to patients with decision-making capacity to provide informed consent. Patient consent should be maintained and monitored throughout the process, and patients should be free to halt their participation voluntarily.
5. Patient selection, surgical treatment, device programming, and comprehensive, regular psychiatric follow-up should be conducted at or supervised by a clinical research center.
6. The investigative team should include specialists from the following disciplines, and they should work in close collaboration:
7a. A functional neurosurgical team with established experience in DBS
8b. A team of psychiatrists with extensive experience in the psychiatric condition under investigation
9c. Preferably, both of the preceding groups should have some experience in neurosurgical treatment for psychiatric disorders. If not, close consultation with experienced centers is indicated
10. Investigators must disclose potential conflicts of interest to regulatory bodies such as ethics committees or institutional review boards and to potential enrollees during the informed consent process.
11. The surgery should be performed only to restore normal function and relieve patients' distress and suffering.
12. The procedure should be performed to improve patients' lives and never for political, law enforcement, or social purposes.

DBS for OCD has fortunately not resulted in significant adverse events. As is common in DBS for movement disorders, stimulation-induced side effects have generally been effectively managed by changing programming parameters. In Greenberg's series, emotional, motor, and olfactory/taste effects were observed with initiation of DBS, but abated after altering stimulation parameters, or deactivating the DBS device. One patient had an isolated intraoperative seizure, but has been seizure-free without treatment since the procedure. Seizures have occurred in animal studies that used parameters similar to those used in OCD patients, namely large pulse widths and high stimulation frequency. One patient had recurrent memory experiences of the surgery, which abated with parameter adjustment, a fact that could be explained by hippocampal connections to the nearby nucleus accumbens (43). Weight gain has been noted in some studies, both when the nucleus accumbens and the inferior thalamic peduncle were targets, and for the former may be mediated by connections between the nucleus accumbens and the lateral hypothalamus (43, 56).

**5.6. Ethics**

These early promising results of DBS for OCD have engendered much enthusiasm for a psychosurgical renaissance. Even before the use of DBS for OCD, ¾ of a random sample of American Psychiatric Association members stated that they would consider referring patients for neurosurgical treatment of intractable OCD (59). It is important and praiseworthy that the advent of the

application of DBS technology to psychiatric disorders has been accompanied by an earnest attempt to avoid the mistakes that sullied the early history of modern psychosurgery. To this end, an extensive and thorough set of standards for a cautious, multidisciplinary application of DBS to OCD has been proposed (Table 3) (60). The requirements aim to protect the vulnerable psychiatric population in investigational studies that explore the application of this therapy, which is still in at an experimental stage.

**6. PERSPECTIVE**

Researchers are just beginning to look back on the first generation of patients treated with DBS for movement disorders, and are now beginning to look forward to the use of DBS for OCD. Early results have been promising, but at this stage there are several unresolved questions. Such questions include: What is the underlying pathophysiology of the disorder? (A topic of intense interest not just in neuroanatomic or neurosurgical arenas, but in genetic, pharmacologic, and physiologic circles as well.) Which patients, or subsets of patients, are likely to benefit? Which is the best target, or would stimulation at different targets affect different aspects of the disease? Programming issues also await further study, as more experience accumulates with the small but growing cohort of patients currently enrolled in various protocols around the world.

As the use of deep brain stimulation becomes increasingly widespread in the wake of its success in the treatment of Parkinson's disease and essential tremor, the application of DBS technology to the worldwide burden of OCD will undoubtedly be appealing. Before advocating the general application of DBS for OCD, however, further study is warranted under carefully designed multidisciplinary trials prepared to responsibly deal with the uncertainty surrounding these experimental procedures. Given the sensitive nature of the history of psychiatric neurosurgery, this is widely understood. On the other hand, it should be emphasized that the significant and widespread suffering attributable to obsessive compulsive disorder warrants active investigation to answer the important questions surrounding this promising therapeutic modality.

**7. ACKNOWLEDGEMENTS**

We thank Dave Peace for his excellent illustrations and quick responses.

**8. REFERENCES**

1. American Psychiatric Association: Diagnostic and statistical manual of mental disorders. Text revision. American Psychiatric Association, Washington, D.C. (2000)
2. S. L. Rauch, D. D. Dougherty, D. Malone, A. Rezaei, G. Friehs, A. J. Fischman, N. M. Alpert, S. N. Haber, P. H. Stypulkowski, M. T. Rise, S. A. Rasmussen, B. D. Greenberg: A functional neuroimaging investigation of



## DBS for OCD

- deep brain stimulation in patients with obsessive-compulsive disorder. *J Neurosurg*, 104, 558-65 (2006)
3. S. A. Rasmussen, J. L. Eisen: The epidemiology and clinical features of obsessive compulsive disorder. *Psychiatr Clin North Am*, 15, 743-58 (1992)
  4. A. Khan, R. M. Leventhal, S. Khan, W. A. Brown: Suicide risk in patients with anxiety disorders: a meta-analysis of the FDA database. *J Affect Disord*, 68, 183-90 (2002)
  5. E. Hollander, C. A. Bienstock, L. M. Koran, S. Pallanti, D. Marazziti, S. A. Rasmussen, L. Ravizza, C. Benkelfat, S. Saxena, B. D. Greenberg, Y. Sasson, J. Zohar: Refractory obsessive-compulsive disorder: state-of-the-art treatment. *J Clin Psychiatry*, 63 Suppl 6, 20-9 (2002)
  6. B. D. Greenberg, L. H. Price, S. L. Rauch, G. Friehs, G. Noren, D. Malone, L. L. Carpenter, A. R. Rezai, S. A. Rasmussen: Neurosurgery for intractable obsessive-compulsive disorder and depression: critical issues. *Neurosurg Clin N Am*, 14, 199-212 (2003)
  7. G. Skoog, I. Skoog: A 40-year follow-up of patients with obsessive-compulsive disorder. *Arch Gen Psychiatry*, 56, 121-7 (1999)
  8. D. S. Husted, N. A. Shapira: A review of the treatment for refractory obsessive-compulsive disorder: from medicine to deep brain stimulation. *CNS Spectr*, 9, 833-47 (2004)
  9. D. E. Sakas, I. G. Panourias, E. Singounas, B. A. Simpson: Neurosurgery for psychiatric disorders: from the excision of brain tissue to the chronic electrical stimulation of neural networks. *Acta Neurochir Suppl*, 97, 365-74 (2007)
  10. G. R. Cosgrove, S. L. Rauch: Psychosurgery. *Neurosurg Clin N Am*, 6, 167-76 (1995)
  11. Per Mindus, Bjorn Meyerson: Anterior capsulotomy for intractable anxiety disorders. In: Operative neurosurgical techniques: indications, methods, and results. Ed: Sweet W, Schmidek H. W.B. Saunders, Philadelphia, PA (1995)
  12. J. G. Modell, J. M. Mountz, G. C. Curtis, J. F. Greden: Neurophysiologic dysfunction in basal ganglia/limbic striatal and thalamocortical circuits as a pathogenetic mechanism of obsessive-compulsive disorder. *J Neuropsychiatry Clin Neurosci*, 1, 27-36 (1989)
  13. M. A. Jenike: Neurosurgical treatment of obsessive-compulsive disorder. *Br J Psychiatry Suppl* 79-90 (1998)
  14. Per Mindus, M. A. Jenike: Neurosurgical treatment of malignant obsessive compulsive disorder. *Psychiatr Clin North Am*, 15, 921-38 (1992)
  15. J. L. Abelson, G. C. Curtis, O. Sagher, R. C. Albucher, M. Harrigan, S. F. Taylor, B. Martis, B. Giordani: Deep brain stimulation for refractory obsessive-compulsive disorder. *Biol Psychiatry*, 57, 510-6 (2005)
  16. B. D. Greenberg, D. A. Malone, G. M. Friehs, A. R. Rezai, C. S. Kubu, P. F. Malloy, S. P. Salloway, M. S. Okun, W. K. Goodman, S. A. Rasmussen. Three-Year outcomes in deep brain stimulation for highly resistant obsessive-compulsive disorder. *Neuropsychopharmacology*, 31, 2384-93 (2006)
  17. G. Knight: Stereotactic Tractotomy in the Surgical Treatment of Mental Illness. *J Neurol Neurosurg Psychiatry*, 28, 304-10 (1965)
  18. R. Strom-Olsen, S. Carlisle: Bi-frontal stereotactic tractotomy. A follow-up study of its effects on 210 patients. *Br J Psychiatry*, 118, 141-54 (1971)
  19. E. O. Goktepe, L. B. Young, P. K. Bridges: A further review of the results of stereotactic subcaudate tractotomy. *Br J Psychiatry*, 126, 270-80 (1975)
  20. J. R. Bartlett, P. K. Bridges: The extended subcaudate tractotomy lesion. In: Neurosurgical treatment in psychiatry, pain, and epilepsy : (proceedings of the Fourth World Congress of Psychiatric Surgery, September 7-10, 1975, Madrid, Spain). Eds: William Herbert Sweet, Sixto Obrador, José G. Martín-Rodríguez. University Park Press, Baltimore (1977)
  21. David Christmas, I. Crombie, M. S. Eljamel, N. Fineberg, R. MacVicar, K. Matthews, C. Ruck, C. Stark: Neurosurgery for obsessive-compulsive disorder, other anxiety disorders and depressive disorders. *Cochrane Database Syst Rev*, 4, (2005)
  22. Michael Jenike, Scott Rauch, Lee Baer, Steven Rasmussen: Neurosurgical treatment of obsessive-compulsive disorder. In: Obsessive-compulsive disorders: practical management. . Ed: Baer L, Jenike M, Minichiello W. Mosby, St. Louis, MO (1998)
  23. H. T. Ballantine, Jr., A. J. Bouckoms, E. K. Thomas, I. E. Giriunas: Treatment of psychiatric illness by stereotactic cingulotomy. *Biol Psychiatry*, 22, 807-19 (1987)
  24. D. D. Dougherty, L. Baer, G. R. Cosgrove, E. H. Cassem, B. H. Price, A. A. Nierenberg, M. A. Jenike, S. L. Rauch: Prospective long-term follow-up of 44 patients who received cingulotomy for treatment-refractory obsessive-compulsive disorder. *Am J Psychiatry*, 159, 269-75 (2002)
  25. C. H. Kim, J. W. Chang, M. S. Koo, J. W. Kim, H. S. Suh, I. H. Park, H. S. Lee: Anterior cingulotomy for refractory obsessive-compulsive disorder. *Acta Psychiatr Scand*, 107, 283-90 (2003)
  26. D. Kelly, A. Richardson, N. Mitchell-Heggs: Stereotactic limbic leucotomy: neurophysiological aspects

## DBS for OCD

- and operative technique. *Br J Psychiatry*, 123, 133-40 (1973)
27. T Bingley, Lars Leksell, Bjorn Meyerson, G. Rylander: Long-term results of stereotactic anterior capsulotomy in chronic obsessive-compulsive neurosis. In: Neurosurgical treatments in psychiatry, pain and epilepsy. Eds: W. Sweet, S. Obrador, J. Martin-Rodríguez. University Park Press, Baltimore, MD (1977)
28. P. Mindus, S. A. Rasmussen, C. Lindquist: Neurosurgical treatment for refractory obsessive-compulsive disorder: implications for understanding frontal lobe function. *J Neuropsychiatry Clin Neurosci*, 6, 467-77 (1994)
29. R. Waziri: Psychosurgery for anxiety and obsessive-compulsive disorder. In: Handbook of Anxiety. Treatment of Anxiety. Eds: R Jr Noyes, M Roth, D. G. Burrows. Elsevier Science Publisher, Amsterdam (1990)
30. E. Antonio Chiocca, Robert L. Martuza: Neurosurgical therapy of obsessive-compulsive disorder. In: Obsessive compulsive disorder: theory and management. Eds: J. Jenike, L. Baer, W. Minichiello. Year Book Medical Publishers, Chicago, IL (1990)
31. L. Gabriels, P. Cosyns, B. Nuttin, H. Demeulemeester, J. Gybels: Deep brain stimulation for treatment-refractory obsessive-compulsive disorder: psychopathological and neuropsychological outcome in three cases. *Acta Psychiatr Scand*, 107, 275-82 (2003)
32. G. E. Alexander, M. R. DeLong, P. L. Strick: Parallel organization of functionally segregated circuits linking basal ganglia and cortex. *Annu Rev Neurosci*, 9, 357-81 (1986)
33. G. E. Alexander, M. D. Crutcher, M. R. DeLong: Basal ganglia-thalamocortical circuits: parallel substrates for motor, oculomotor, "prefrontal" and "limbic" functions. *Prog Brain Res*, 85, 119-46 (1990)
34. T. Wichmann, M. R. DeLong: Deep brain stimulation for neurologic and neuropsychiatric disorders. *Neuron*, 52, 197-204 (2006)
35. L. Mallet, V. Mesnage, J. L. Houeto, A. Pelissolo, J. Yelnik, C. Behar, M. Gargiulo, M. L. Welter, A. M. Bonnet, B. Pillon, P. Cornu, D. Dormont, B. Pidoux, J. F. Allilaire, Y. Agid: Compulsions, Parkinson's disease, and stimulation. *Lancet*, 360, 1302-4 (2002)
36. D. Fontaine, V. Mattei, M. Borg, D. von Langsdorff, M. N. Magnie, S. Chanalet, P. Robert, P. Paquis: Effect of subthalamic nucleus stimulation on obsessive-compulsive disorder in a patient with Parkinson disease. Case report. *J Neurosurg*, 100, 1084-6 (2004)
37. S. Saxena, A. L. Brody, J. M. Schwartz, L. R. Baxter: Neuroimaging and frontal-subcortical circuitry in obsessive-compulsive disorder. *Br J Psychiatry Suppl* 26-37 (1998)
38. A. L. Benabid, P. Pollak, A. Louveau, S. Henry, J. de Rougemont: Combined (thalamotomy and stimulation) stereotactic surgery of the VIM thalamic nucleus for bilateral Parkinson disease. *Appl Neurophysiol*, 50, 344-6 (1987)
39. A. L. Benabid: Deep brain stimulation for Parkinson's disease. *Curr Opin Neurobiol*, 13, 696-706 (2003)
40. S. Breit, J. B. Schulz, A. L. Benabid: Deep brain stimulation. *Cell Tissue Res*, 318, 275-88 (2004)
41. M. Ushe, J. W. Mink, F. J. Revilla, A. Wernle, P. Schneider Gibson, L. McGee-Minnich, M. Hong, K. M. Rich, K. E. Lyons, R. Pahwa, J. S. Perlmutter: Effect of stimulation frequency on tremor suppression in essential tremor. *Mov Disord*, 19, 1163-8 (2004)
42. N. P. Stover, M. S. Okun, M. L. Evatt, D. V. Raju, R. A. Bakay, J. L. Vitek: Stimulation of the subthalamic nucleus in a patient with Parkinson disease and essential tremor. *Arch Neurol*, 62, 141-3 (2005)
43. K. van Kuyck, L. Gabriels, P. Cosyns, L. Arckens, V. Sturm, S. Rasmussen, B. Nuttin: Behavioural and physiological effects of electrical stimulation in the nucleus accumbens: a review. *Acta Neurochir Suppl*, 97, 375-91 (2007)
44. N. D. Schiff, J. T. Giacino, K. Kalmar, J. D. Victor, K. Baker, M. Gerber, B. Fritz, B. Eisenberg, J. O'Connor, E. J. Kobylarz, S. Farris, A. Machado, C. McCagg, F. Plum, J. J. Fins, A. R. Rezaei: Behavioural improvements with thalamic stimulation after severe traumatic brain injury. *Nature*, 448, 600-3 (2007)
45. A. L. Benabid, S. Chabardes, E. Seigneuret, P. Pollak, V. Fraix, P. Krack, J. F. Lebas, S. Grand, B. Piallat: Functional neurosurgery: past, present, and future. *Clin Neurosurg*, 52, 265-70 (2005)
46. B. Nuttin, P. Cosyns, H. Demeulemeester, J. Gybels, B. Meyerson: Electrical stimulation in anterior limbs of internal capsules in patients with obsessive-compulsive disorder. *Lancet*, 354, 1526 (1999)
47. B. J. Nuttin, L. A. Gabriels, P. R. Cosyns, B. A. Meyerson, S. Andreewitch, S. G. Sunaert, A. F. Maes, P. J. Dupont, J. M. Gybels, F. Gielen, H. G. Demeulemeester: Long-term electrical capsular stimulation in patients with obsessive-compulsive disorder. *Neurosurgery*, 52, 1263-72; discussion 1272-4 (2003)
48. B. Aouizerate, E. Cuny, C. Martin-Guehl, D. Guehl, H. Amieva, A. Benazzouz, C. Fabrigoule, M. Allard, A. Rougier, B. Bioulac, J. Tignol, P. Burbaud: Deep brain stimulation of the ventral caudate nucleus in the treatment of obsessive-compulsive disorder and major depression. Case report. *J Neurosurg*, 101, 682-6 (2004)

## DBS for OCD

49. B. Aouizerate, C. Martin-Guehl, E. Cuny, D. Guehl, H. Amieva, A. Benazzouz, C. Fabrigoule, B. Bioulac, J. Tignol, P. Burbaud: Deep brain stimulation for OCD and major depression. *Am J Psychiatry*, 162, 2192 (2005)
50. B. J. Nuttin, L. Gabriels, K. van Kuyck, P. Cosyns: Electrical stimulation of the anterior limbs of the internal capsules in patients with severe obsessive-compulsive disorder: anecdotal reports. *Neurosurg Clin N Am*, 14, 267-74 (2003)
51. P. A. Tass, J. Klosterkotter, F. Schneider, D. Lenartz, A. Koulousakis, V. Sturm: Obsessive-compulsive disorder: development of demand-controlled deep brain stimulation with methods from stochastic phase resetting. *Neuropsychopharmacology*, 28 Suppl 1, S27-34 (2003)
52. N. Lipsman, J. S. Neimat, A. M. Lozano: Deep brain stimulation for treatment-refractory obsessive-compulsive disorder: the search for a valid target. *Neurosurgery*, 61, 1-11; discussion 11-3 (2007)
53. M. S. Okun, D. Bowers, U. Springer, N. A. Shapira, D. Malone, A. R. Rezai, B. Nuttin, K. M. Heilman, R. J. Morecraft, S. A. Rasmussen, B. D. Greenberg, K. D. Foote, W. K. Goodman: What's in a "smile?" Intra-operative observations of contralateral smiles induced by deep brain stimulation. *Neurocase*, 10, 271-9 (2004)
54. V. Sturm, D. Lenartz, A. Koulousakis, H. Treuer, K. Herholz, J. C. Klein, J. Klosterkotter: The nucleus accumbens: a target for deep brain stimulation in obsessive-compulsive- and anxiety-disorders. *J Chem Neuroanat*, 26, 293-9 (2003)
55. N. Swerdlow, G. Koob: Dopamine, schizophrenia, mania and depression: toward a unified hypothesis of cortico-striatal-pallido-thalamic function. *Behav Brain Sci* 10, 197-245 (1987)
56. F. Jimenez, F. Velasco, R. Salin-Pascual, M. Velasco, H. Nicolini, A. L. Velasco, G. Castro: Neuromodulation of the inferior thalamic peduncle for major depression and obsessive compulsive disorder. *Acta Neurochir Suppl*, 97, 393-8 (2007)
57. M. S. Okun, G. Mann, K. D. Foote, N. A. Shapira, D. Bowers, U. Springer, W. Knight, P. Martin, W. K. Goodman: Deep brain stimulation in the internal capsule and nucleus accumbens region: responses observed during active and sham programming. *J Neurol Neurosurg Psychiatry*, 78, 310-4 (2007)
58. S. N. Haber: The primate basal ganglia: parallel and integrative networks. *J Chem Neuroanat*, 26, 317-30 (2003)
59. S. J. Mathew, S. C. Yudofsky, L. B. McCullough, T. A. Teasdale, J. Jankovic: Attitudes toward neurosurgical procedures for Parkinson's disease and obsessive-compulsive disorder. *J Neuropsychiatry Clin Neurosci*, 11, 259-67 (1999)
60. B. Nuttin, J. Gybels, P. Cosyns, L. Gabriels, B. Meyerson, S. Andreewitch, S. Rasmussen, B. Greenberg, G. Friehs, A. Rezai, E. Montgomery, D. Malone, J. Fins: Deep brain stimulation for psychiatric disorders. *Neurosurgery*, 51, 519 (2002)
61. D. Anderson, A. Ahmed: Treatment of patients with intractable obsessive-compulsive disorder with anterior capsular stimulation. Case report. *J Neurosurg*, 98, 1104-8 (2003)

**Abbreviations:** AC, anterior commissure; ALIC, anterior limb of the internal capsule; CT, computed tomography; DBS, deep brain stimulation; FDG, 18F-fluorodeoxyglucose; GPi, globus pallidus interna; HMPAO, 99m-technetium-d,l-hexamethyl propyleneamine oxime; Hz, hertz; msec, millisecond; ITP, inferior thalamic peduncle; MRI, magnetic resonance imaging; NACC, nucleus accumbens; OCD, obsessive-compulsive disorder; PD, Parkinson's Disease; PET, positron emission tomography; SNr, substantia nigra; SPECT, single photon emission computed tomography; STN, subthalamic nucleus; V, volt; VC/VS, ventral capsule/ventral striatum; Y-BOCS, Yale-Brown Obsessive Compulsive Scale

**Key Words:** Deep brain Stimulation, DBS, Obsessive-Compulsive Disorder, OCD, Refractory, Psychosurgery, Neuromodulation, Review

**Send correspondence to:** Kelly D. Foote, University of Florida, Department of Neurosurgery, PO Box 100265, Gainesville, FL, 32610, Tel: 352-273-9000, Fax: 352-392-8413, E-mail: foote@neurosurgery.ufl.edu

<http://www.bioscience.org/current/vol14.htm>